

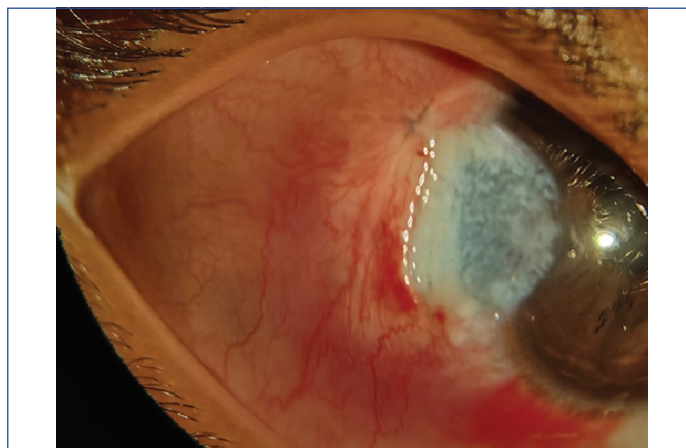
Temporal Limbal Dermoid in a Six-year-old Child with Induced Astigmatism: Images in Medicine

MOHAMMED ARIF KADERI¹, SACHIN VISHWANATH DAIGAVANE²

Keywords: Dermoid cyst, Goldenhar syndrome, Hairy mass, Paediatric patient, Ocular finding, White tissue

A six-year-old boy presented to the Outpatient Department of Ophthalmology with the chief complaint of growth of a white, hairy mass in the right eye since birth, which had gradually increased in size over time. The parents sought medical advice when the lesion enlarged and the child began experiencing foreign body like sensation. He was born full-term with normal developmental milestones.

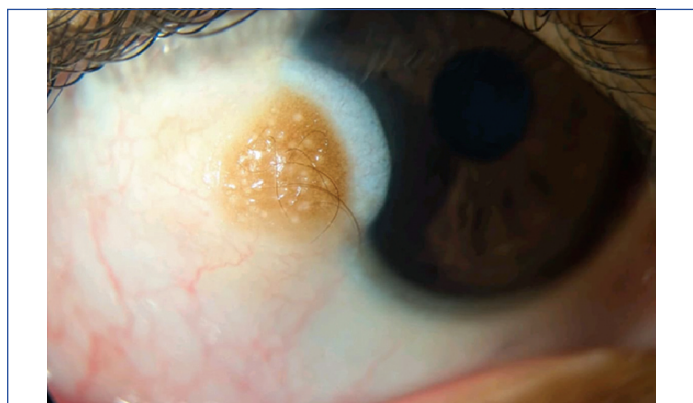On Ultrasonography (USG) examination, there was a 6.9×1.6 mm lesion with superficial stromal involvement suggestive of a dermoid cyst lesion. On the ocular and slit lamp examination, the cornea of the right eye revealed a temporal limbal dermoid cyst involving the corneal periphery [Table/Fig-1]. Preoperative cycloplegic refraction of the right eye revealed +0.75 Diopter Sphere (DS)/-3.75 Diopter Cylinder (DC) × 180°, correlating with a Best-Corrected Visual Acuity (BCVA) of 6/12. The astigmatism was consistent with a temporal limbal dermoid inducing corneal surface irregularity. The patient underwent surgical excision under short sedation. After establishing proper anaesthesia, the ocular surface was prepared and draped in a sterile manner. The limbal dermoid was precisely defined, and a shallow incision was performed along its edges. The cyst was carefully separated from the surrounding corneal and conjunctival tissue and completely excised. The remaining surface defect was smoothed, and conjunctival tissue was relocated or transplanted as necessary. The excised specimen consisted of a single, irregular, whitish tissue fragment measuring 0.6×0.5×0.5 cm, which revealed histopathological features of dermoid cyst. Postoperatively, the patient was started on topical moxifloxacin 0.5% four times daily for two weeks, prednisolone acetate 1% four times daily tapered over four weeks, and preservative-free carboxymethylcellulose 0.5% six times daily for four weeks. At six weeks postoperatively, cycloplegic refraction showed +0.50 DS / -2.00 DC × 180°, with improvement in BCVA to 6/9 with correction. The reduction in cylindrical error suggested partial regularisation of the corneal surface following surgical excision [Table/Fig-2].



[Table/Fig-2]: Postoperative appearance following complete surgical excision of limbal dermoid.

at the inferotemporal limbus. It may occur in isolation and as part of syndromic associations such as Goldenhar syndrome. It often affects the superficial corneal stroma and, depending on its grade, may spread into deeper layers, resulting in surface irregularity and corneal opacity. Because limbal dermoids can produce astigmatism by changing the curvature of the cornea by either direct stromal infiltration or localised flattening, corneal involvement is clinically relevant. If left untreated, this can lead to anisometropic amblyopia [1,2]. Lesion size and corneal penetration depth are frequently correlated with the amount of produced astigmatism. The following conditions are considered surgical indications: visually severe astigmatism or amblyopia risk, persistent irritation, recurring inflammation, progressive enlargement, and considerable cosmetic concern. While superficial lesions can be treated with simple excision, bigger or deeper lesions may necessitate amniotic membrane transplantation or lamellar keratoplasty [1,2]. When prompt intervention is implemented, especially in paediatric patients receiving early refractive correction and amblyopia treatment, visual results are often favourable; nevertheless, residual astigmatism may continue even after successful excision [1,2].

For the diagnosis and treatment of orbital and ocular dermoid cysts, Computed Tomography (CT) and Magnetic Resonance Imaging (MRI) are essential, especially when lesions are deep-seated or close to important structures [3]. For preoperative planning, CT is particularly helpful in pinpointing the precise anatomical position, evaluating bony involvement, and detecting distinctive characteristics such as fat density, calcification, bone remodelling, or scalloping [4]. Particularly in complex cases involving proximity to the optic nerve, extraocular muscles, or intracranial structures, combined CT and MRI imaging allows for precise assessment of lesion size, tissue involvement, rupture, inflammation, and cyst characterisation, thereby guiding appropriate surgical or conservative management [5]. Early detection and adequate surgical excision are critical to



[Table/Fig-1]: Preoperative photograph showing the presence of hairy whitish mass in the temporal limbal region on the right eye, consistent with dermoid cyst.

Limbal dermoid is a congenital benign choristoma composed of ectopic dermal and adnexal elements, most commonly located

avoiding rupture, inflammation, and subsequent problems such as abscess development or scarring [6]. Previously reported cases highlighting the clinical presentation and management strategies based on lesion location and extent [Table/Fig-3] [3,6-9].

Study	Age	Clinical presentation	Key imaging/Findings
Salma M et al., (2024) [3]	5-year-old boy	Slowly progressive limitation of right ocular motility without pain or proptosis	Well-circumscribed extraconal cystic mass on CT/MRI; benign dermoid confirmed on histology
Lin Y et al., (2023) [7]	29-month-old girl	Bilateral eyebrow/orbital swelling	Bilateral dermoid cysts were successfully excised
Al-Ghadeer H et al., (2021) [8]	4-year-old girl	Bilateral inferotemporal limbal dermoids. The left eye had a larger lesion encroaching on the visual axis with reduced visual acuity, while the right eye had a smaller peripheral lesion.	Limbal dermoid excision and lamellar keratoplasty were performed in the left eye, followed by a simple excision of the limbal dermoid in the right eye.
Bajric J et al., (2020) [9]	≤5 years	Superotemporal orbital rim mass	Epidemiologic series; imaging-guided surgical excision
Cavazza S et al., (2011) [6]	6-84 months	Palpable orbital mass, sometimes ptosis	Superficial vs deep dermoids classified by imaging; complete excision

[Table/Fig-3]: Similar cases with their clinical presentation and key imaging/findings [3,6-9].

REFERENCES

- [1] Pirouzian A. Management of pediatric corneal limbal dermoids. *Clin Ophthalmol.* 2013;7:607-14. Doi: 10.2147/OPHTH.S38663.
- [2] Guarnera A, Valente P, Pasquini L, Moltoni G, Randisi F, Carducci C, et al. Congenital malformations of the eye: A pictorial review and clinico-radiological correlations. *J Ophthalmol.* 2024;2024:5993083. Doi: 10.1155/2024/5993083.
- [3] Salma M, Salma EA, Yahya EH, Samia S, Ihssan HH, Sabrine D, et al. Orbital dermoid cyst in children: A case report. *Radiol Case Rep.* 2024 Oct 17;20(1):140-44. Doi: 10.1016/j.radcr.2024.09.124.
- [4] Kumar R, Vyas K, Jaiswal G, Bhargava A, Kundu J. Deep orbital dermoid cyst bulging into the superior orbital fissure: Clinical presentation and management. *J Ophthalmic Vis Res.* 2017;12(1):110-12.
- [5] Shao Y, Ma JM, Huang XM; Expert Workgroup of Guidelines for the use of imaging equipment in orbital diseases (2024); Ophthalmic Imaging and Intelligent Medicine Branch Chinese Medicine Education Association; Ocular Oncology Committee of the Ophthalmology Branch of the Chinese Medical Doctor Association; Ophthalmology Committee of International Association of Translational Medicine; Chinese Ophthalmic Imaging Study Groups. Guidelines for standard operation of imaging modalities in orbital diseases (2024). *Int J Ophthalmol.* 2025;18(1):51-66. Doi: 10.18240/ijo.2025.01.06.
- [6] Cavazza S, Laffi GL, Lodi L, Gasparini E, Tassinari G. Orbital dermoid cyst of childhood: Clinical pathologic findings, classification and management. *Int Ophthalmol.* 2011;31(2):93-97. Doi: 10.1007/s10792-011-9419-y.
- [7] Lin Y, Cui J, Zhang H, Huang S. Bilateral orbital dermoid cysts: A case report. *J Int Med Res.* 2023;51(12):3000605231218634.
- [8] Al-Ghadeer H, Khandekar R. Bilateral limbal dermoid as an isolated finding in a child. *J Pediatr Ophthalmol Strabismus.* 2021;58(4):e27-e29. Doi: 10.3928/01913913-20210506-01.
- [9] Bajric J, Harris GJ. The spectrum of orbital dermoid cysts and their surgical management. *Orbit.* 2020;39(4):266-75. Doi: 10.1080/01676830.2019.1631357.

PARTICULARS OF CONTRIBUTORS:

1. Postgraduate Student, Department of Ophthalmology, Jawaharlal Nehru Medical College, Datta Meghe Institute of Higher Education and Research, Wardha, Maharashtra, India.
2. Professor and Head, Department of Ophthalmology, Jawaharlal Nehru Medical College, Datta Meghe Institute of Higher Education and Research, Wardha, Maharashtra, India.

NAME, ADDRESS, E-MAIL ID OF THE CORRESPONDING AUTHOR:

Dr. Mohammed Arif Kaderi,
Postgraduate Student, Department of Ophthalmology, AVBRH Hospital,
Sawangi, Wardha-442107, Maharashtra, India.
E-mail: mkad11@hotmail.com

PLAGIARISM CHECKING METHODS: [Jain H et al.]

- Plagiarism X-checker: Jan 05, 2026
- Manual Googling: Apr 02, 2026
- iThenticate Software: Apr 04, 2026 (1%)

ETYMOLOGY: Author Origin

EMENDATIONS: 6

AUTHOR DECLARATION:

- Financial or Other Competing Interests: None
- Was informed consent obtained from the subjects involved in the study? Yes
- For any images presented appropriate consent has been obtained from the subjects. Yes

Date of Submission: **Dec 06, 2025**
Date of Peer Review: **Feb 12, 2026**
Date of Acceptance: **Apr 06, 2026**
Date of Publishing: **Jul 01, 2026**